

Oxygen-enriched oleic matrix medical dressings for the treatment of extensive burns and related acute and post-burn complications in children: a case series

A dressing with an oleic matrix (organic extra virgin olive oil) enriched with oxygen capable of releasing limited quantities of reactive oxygen species (ROS) was used for extensive paediatric burns, with the aims of reducing healing times, improving the healing process, and controlling infection, post-burn itching and scarring. Three cases of paediatric second and third degree burns, caused by hot liquids and backfire, are presented. In all three cases, the burn had a total body surface area >15%. In the post-discharge evaluation, complications were detected, including infection and hypergranulation. During the treatment period, the children tolerated the matrix well, not reporting itching or burning sensations. No adverse events were noted. The healing outcomes were good, with resolution of the infection and prevention of hypertrophic scars. The results obtained suggest that the application of the dressing in the context of paediatric burns, may represent a safe and effective treatment, with no significant identified negative effects. The dressing promoted tissue repair by managing and controlling major acute complications, primarily the infection and oxidative stress, and the related post-acute consequences, itching and scar hypertrophy.

Burns are traumatic events that can be caused by several aetiological agents, including friction, cold, heat, radiation, chemical or electrical sources; however, most burns are caused by hot liquids, solids or flame (Jeschke et al, 2020).

Burns cause tissue destruction due to the transfer of energy, which is in turn conditioned by the burning agent. For example:

- Flame burns or hot fatty substances may immediately result in a deep injury.
- Burns from hot liquids or steam will initially appear more superficial, due to the fast rate of fading of the source and energy.
- Low temperature, e.g. frostbite, is caused by several mechanisms, including direct cellular damage due to water crystallisation in the tissues and indirect damage due to ischaemia and reperfusion.
- Alkaline chemicals cause necrosis, where the tissue is turned into a viscous liquid mass.
- Acids cause coagulative necrosis, so the architecture of the dead tissue can be preserved.
- Electrical injuries are highly variable, depending on the magnitude of the electric field and tissue electrical resistance (Lee, 1997).

All these mechanisms lead not only to skin

necrosis, but also to deep tissue damage; this implies that the treatment strategy is heavily influenced by the cause of the burn determines the treatment approach (Jeschke et al, 2020).

Burns represent a global public health issue, which is responsible for approximately 180,000 fatal events (deaths) per year. Most of these occur in low- and middle-income countries. Nonfatal burns are a major cause of morbidity, including prolonged hospitalisation, disfigurement, and disability, often resulting in stigma and rejection (Smolle et al, 2017).

Children are especially vulnerable to burns. Burns are the fifth most common cause of non-fatal childhood injuries. Children are usually burned in home kitchens, by overturned containers containing hot liquids or flames, or by stove explosions (Smolle et al, 2017).

The burn, either when it is extensive and deep, or it affects limited but highly noticeable areas, such as hands and face, undoubtedly represents one of the worst injuries a person can suffer (Sri, 2022).

The impact of a burn is devastating, not only during the entire course of the disease in the acute phase, but also after the complete healing of the lesions, due to the very serious functional, aesthetic, and psychological problems that can be connected to the

Authors

Biagio Nicolosi

RN, Burns Unit and Complex Wounds, Department Health Professions, Meyer Children's Hospital IRCCS, Florence, Italy

Pablo García-Molina

RN, MSc, PhD, Complex Wounds, Hospital Clínico Valencia, Faculty of Nursing, University of Valencia, Associated care research group (INCLIVA), Valencia, Spain

Stefania Veggì

RN, Coordinator Nurse, Department of Pediatric Surgery and Health Professions, Meyer Children's Hospital IRCCS, Florence, Italy

Enrico Pinzauti

MD, General and Burns Surgeon, Burns Unit, Department of Pediatric Surgery, Meyer Children's Hospital IRCCS, Florence, Italy

Simone Pancani

MD, General and Burns Surgeon, Burns Unit, Department of Pediatric Surgery, Meyer Children's Hospital IRCCS, Florence, Italy

Key words

- Paediatric burns
- Oxygen-enriched oleic matrix
- Post-burn complications
- Healing process
- Advanced dressings

Declaration

The authors have no conflicts of interest to disclose.

Table 1. Critical extent of burns by age	
0–12 months	> 5%
1–4 years	> 8%
>4 years	> 10%
>14 years	> 18%

disfiguring and disabling scarring. When burns affect children, its management becomes even more complex and sensitive, due to epidemiological, anatomical-physiological, psychological characteristics, treatment path and healing process of the injured areas (Sri, 2022).

The main parameters that are used to classify burns are the affected surface area (as percentage of total body surface area [TBSA]) and the depth. Additional parameters may be the location of the burn and the age of the patient (Sri, 2022).

Although shallow and superficial partial thickness burns usually heal without surgery, more severe burns require careful management, including topical antimicrobial medications and/or surgery (Markiewicz-Gospodarek et al, 2022).

Burns are classified as minor or major, based on their extent: a minor burn is usually defined as a burn affecting <10% TBSA, with a predominance of superficial burns.

There is less agreement on what TBSA percentage should be defined as a severe burn. Some indications suggest >10% TBSA in elderly patients, >20% TBSA in adults and >30% TBSA in children (Jeschke et al, 2020).

In children, the severity of a burn is usually defined taking into account both the age and extent [Table 1] (Sri, 2022).

The authors investigated the use of a dressing with oleic matrix (organic extra virgin olive oil) enriched with oxygen capable of releasing limited quantities of reactive oxygen species (ROS), with the aim of reducing healing times for extensive paediatric burns, improving the healing process, controlling infection, post-burn itching and scarring, and improving the children’s quality of life.

A new dressing based on an oxygen-enriched oleic matrix (organic extra virgin olive oil)

Scientists are looking for the gold standard in burn treatment, not only to significantly improve and accelerate the healing process, but also to prevent potential infections and improve healing outcomes. Taking into account the physiopathological characteristics of burn

Table 2. Advanced dressings used	
Dressing	Characteristics of the damaged tissue
Paraffin gauze and collagenase	Bottom with non-viable tissue
Gelling fibre (sodium carboxymethylcellulose) with silver	Cleansed tissue after dermabrasion
Silicon contact layer	Grafted areas

wounds, in particular infection risk and oxidative stress, an optimal dressing should be able to manage both. It should improve the scar outcome, especially for potentially disabling scars (Markiewicz-Gospodarek et al, 2022).

Among the primary causes of repair failure, inflammation appears to be the main culprit and a key role in its maintenance has been identified in the redox system.

The redox system can produce ROS, whose concentration at the cellular level dynamically influences metabolic and environmental signalling responses (Jakubczyk et al, 2020; Casella et al, 2021).

By exploiting the ability to bind oxygen in an olive oil matrix, an oily ointment capable of providing the appropriate local conditions allowing the modulation of the injured tissue response, has been developed. This was then embedded in different supporting scaffolds which allow optimising the contact between the oxygen-enriched oleic matrix and the wound. This allows the release of the product to occur gradually and the product to be packaged depending on the area to be treated (Casella et al, 2021; Santorelli et al, 2021).

The basic principle is that of a main component consisting of an oleic matrix (organic extra virgin olive oil) enriched with oxygen (oxygen-enriched oleic matrix) capable of constantly releasing limited quantities of ROS.

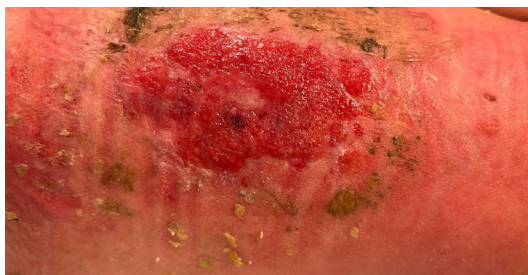
The mechanism of action is based on the following characteristics:

- The dressing facilitates the healing process by creating a microenvironment favourable to the activation of the microcirculation and consequently the natural reparative processes of cell proliferation which guarantee healing of the lesion.
- The dressing carries out an action to combat microbial contamination thanks to the ability to create a local microenvironment unfavourable to the proliferation of pathogens, thanks to the release of ROS.
- The dressing has a film-forming, protective, barrier and soothing action thanks to its oily nature, which also allows to keep a moist wound environment.

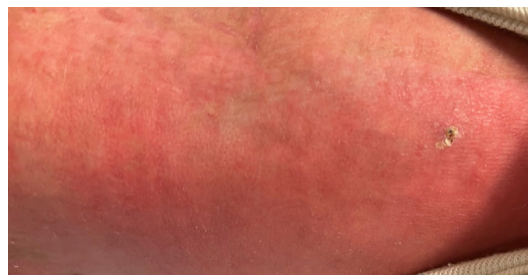Box 1. Case 1. Three-year-old with burn from boiling liquid

- TBSA: 25%
- Burn grade: 3rd, deep 2nd
- Body area: Upper, lower limbs, left hemithorax
- Skin graft after hospitalisation: day 6
- Discharge: day 18
- Detection of complications post discharge and first dressing with oxygen-enriched oleic matrix: day 25
- Secondary dressing: alginate dressing and bandage
- Healed: after 22 days of oxygen-enriched oleic matrix

First dressing with oxygen-enriched oleic matrix

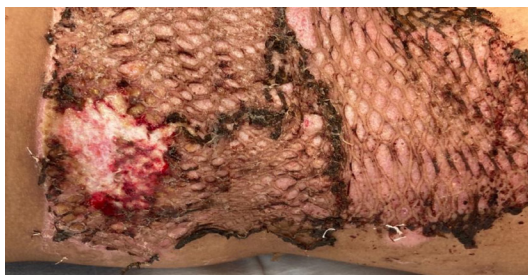

Healed

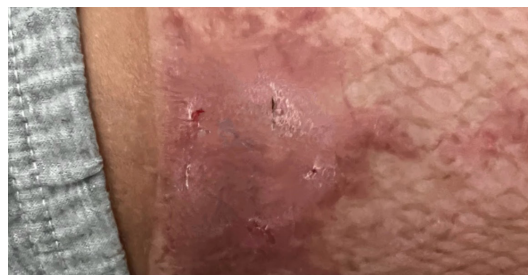**Box 2. Case 2. Seven-year-old with burn from backfire**

- TBSA: 16%
- Burn grade: 3rd, deep 2nd
- Body area: Chest, left arm, chin
- Skin graft after hospitalisation: day 3
- Discharge: day 9
- Detection of complications post discharge and first dressing with oxygen-enriched oleic matrix: day 7
- Secondary dressing: alginate dressing and bandage
- Healed: after 13 days of oxygen-enriched oleic matrix

First dressing with oxygen-enriched oleic matrix



Healed



The dressing has the characteristics to be applied in burn injuries which are not healing, mainly for inflammation and infection. This promotes the healing and consent to prevent hypergranulation, with good final outcomes.

We describe our experience of using this dressing in children.

Case evaluations

After parent and patients provided written informed consent, photographs were taken before and after treatment for all patients. Ethical approval was not required. The cases were reviewed successfully, and patients received treatment according to their clinical condition.

The parameters evaluated were: age, burning agent, TBSA, burn grade, body area, timing skin graft after hospitalisation, discharge, detection complications after discharge, first medication with oleic matrix, secondary dressing healing, after application oleic matrix.

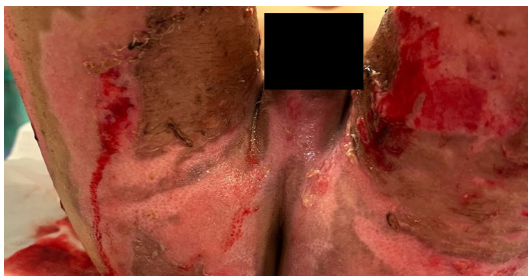The cases described below are paediatric burns, consequent to hot liquid and backfire, which caused second deep grade and third grade burns. The three cases of burns were all classified as extensive lesions, according to the Lund and Browder (1944) chart. The children's average age was 5 years, and all burns had a TBSA > 15%.

All three cases were treated with surgical

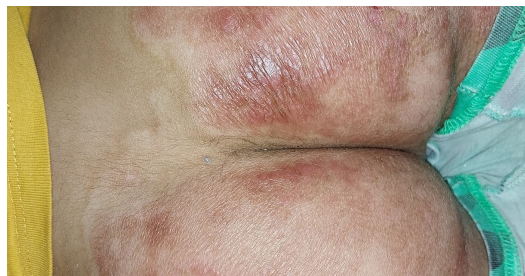Box 3. Case 3. Five-year-old with burn from boiling liquid

- TBSA: 20%
- Burn grade: 3rd, deep 2nd
- Body area: perineal area (buttocks, genitals), upper third of the thighs, right hypochondrium, left forearm, third, fourth and fifth fingers of the left hand, fourth finger of the right hand and dorsum of the left foot
- Skin graft after hospitalisation: day 8
- Discharge: day 11
- Detection of complications post discharge and first dressing with oxygen-enriched oleic matrix: day 7
- Secondary dressing: alginate dressing and bandage
- Healed: after 30 days of oxygen-enriched oleic matrix

First dressing with oxygen-enriched oleic matrix



Healed



interventions of autologous skin grafts and the application of several advanced dressings [Table 2].

In all cases, the first approach was dermabrasion, to remove the escharotic tissue, and application of gelling fibre with silver. In the more superficial areas, in which the bottom was covered partially by non-viable tissue, paraffin gauze and collagenase were applied. The areas which showed no improvement were surgically treated with dermabrasion and autologous skin grafting and were protected using a silicon contact layer. The dressings were kept in place using a non-compressive bandage. The dressings were changed every 3 days, following wound irrigation, excluding the skin graft areas. Before discharge, the children were treated with hydrotherapy, a treatment with water to remove any necrotic residues and reduce the bioburden.

In the post-discharge follow-up evaluation, complications were detected, including infection and hypergranulation. In all three cases, oxygen-enriched oleic matrix dressings were used with the aim of promoting healing in the areas showing no improvement. The Wong-Baker scale (facial expression scale, Garra et al, 2013) was used to assess itching during the hospitalisation and in the post-healing phase, due to its ease of application and interpretation by children.

Parents were advised to use a lipophilic oil with vitamin E and ceramides for 6 months after healing, and to avoid sun exposure in order to improve and consolidate the healing outcomes.

Results

The healing outcomes were good, with resolution of the infection and prevention of the hypertrophic scar formation, following the application of the oxygen-enriched oleic matrix dressing. All the children showed a good tolerance during all the duration of the treatment with the oxygen-enriched oleic matrix dressing, without reported itching or burning sensations. Itching assessment after dressing provided a score not higher than 4 on the Wong-Baker scale, matching the score reported during hospitalisation. No adverse events were observed.

The three cases are summarised in Boxes 1–3, together with a summary of the treatments, and final and intermediate result.

Discussion

The local treatment of burns, using oxygen-enriched oleic matrix medical dressings classified as “advanced dressings”, is based on the interaction with the wound bed changing the local wound microenvironment and ensuring the local conditions are both favourable to tissue restoration and unfavourable to pathogens’ growth, thus preventing the risk of possible biofilm formation, and reducing the inflammatory response, with an indirect action on oxidative stress. The primary advantage is the reduction of healing times and therefore the improvement of healing outcomes (Laureti et al, 2016).

ROS play a key role in biological processes and their production appears to be regulated by a mechanism between high and low

intracellular concentrations. In the literature, the application of reactive oxygen species through oxygen-enriched oil matrices has been evaluated in multiple disciplines and contexts, including the treatment of burn injuries that tend to become chronic, mainly due to the ability of ROS to impair bacterial proliferation, reduce local inflammation and promote re-epithelialisation (Mamounas and Fisher, 2001).

In the treated cases, the modulation of the inflammatory response and the proliferative phase, promoted by local wound environment conditions following the application of oxygen-enriched oil matrix, and by the release of ROS, helped to resolve the infectious component and to normalise the inflammatory response. The topical treatment promoted a significant improvement in local clinical conditions, signs and symptoms and healing outcomes, despite the former difficult healing and the extension of the lesions.

The reduction of pain and the disappearance of the malodour, generally associated to the presence of an infection, was favoured by the mechanism of action of the oxygen-enriched oleic matrix.

Another important symptom in the acute and post-acute treatment of burns is post-burn itching, which occurs during the wound healing process after a burn. Its risk factor appears to be more extensive burns, multiple surgeries, and burns to the limbs and face (Vitale et al, 1991; Sies, 2020).

Acute post-burn itching occurs during the period from wound closure to the remodelling phase of healing. The overall percentages of patients experiencing mild to severe itching were 87%, 70%, and 67% at 3 months, 1 year, and 2 years after the burn, respectively (Zachariah et al, 2012).

The intensity of post-burn itching is usually severe (≥ 5 on the pruritus visual analogue scale; Zachariah et al, 2012). Post-burn pruritus is understudied, and many protocols reflect empirical approaches with limited evidence to support their effectiveness. However, it is difficult to treat post-burn itching using conventional treatments such as topical corticosteroids (Willebrand et al, 2004).

Patients who suffer from post-burn itching have higher subjective scores for pain, stiffness, thickness, erythaema index and irregularity than those who do not. Among the histopathological differences are that the burn scar has a thicker epidermis, has thin and dense collagen bundles, has fewer elastic fibres and has abundant mast cells (Van Loey et al, 2008; Um et al, 2022). Patients most characterised their pain as a "pins and needles" sensation (46%). Other symptoms

reported included stabbing (13%), burning (13%), electricity (7%), shooting (4%), and other painful sensations (32%; Schneider et al, 2006). Post-burn itching can disturb sleep, interfere with social relations and daily activities and may even worsen healing due to damage induced by intractable scratching (Bell et al, 1988). The mechanisms that induce post-burn itching are also involved in the hypertrophy of burn scars, which is why hyperproliferative scars are itchier (Goutos et al, 2010).

All the three children treated with the oxygen-enriched oleic matrix dressing reported no pain, sleep disturbances or other symptoms related to itching. Moreover, the scar outcomes were good, and the children reported no itching.

We could conclude that these results are the consequence of the dressing's anti-bacterial and anti-inflammation action. The dressing is effective and safe in paediatric burns. Our team could study this dressing in other injuries or in a bigger sample.

Limitations

The limitations of this study include its retrospective design and the small number of cases.

Conclusion

The results in these cases, despite being limited in number and not susceptible of a statistical analysis, suggest that the application of the dressing in the context of paediatric burns may represent a safe and effective treatment, with no identified negative effects. The oxygen-enriched oil matrix releases ROS and promoted tissue repair by managing and controlling major acute complications, primarily infection and oxidative stress, and the related post-acute consequences, itching and scar hypertrophy.

Further studies will be necessary to fully understand the potential of oxygen-enriched oil matrices releasing ROS and explore and expand the dressing's capabilities. ●

References

- Bell L, McAdams T, Morgan R et al (1988) Pruritus in burns: a descriptive study. *J Burn Care Rehabil* 9(3): 305–8
- Casella D, Palumbo P, Sandroni S et al (2021) Positive ROS (reactive oxygen species) modulator engineered device support skin treatment in locally advanced breast cancer (LABC) enhancing patient quality of life. *J Clin Med* 11(1): 126
- Garra G, Singer AJ, Domingo A, Thode HC Jr (2013) The Wong-Baker pain FACES scale measures pain, not fear. *Pediatr Emerg Care* 29(1): 17–20
- Goutos I, Eldardiri M, Khan AA et al (2010) Comparative evaluation of antipruritic protocols in acute burns. The emerging value of gabapentin in the treatment of burns pruritus. *J Burn Care Res* 31(1): 57–63

- Jakubczyk K, Dec K, Kaldunska J et al (2020) Reactive oxygen species – sources, functions, oxidative damage. *Pol Merkur Lek* 48(284): 124–7
- Jeschke MG, van Baar ME, Choudhry MA et al (2020) Burn injury. *Nat Rev Dis Primers* 6(1): 11
- Laureti S, Aborajoh E, Mattioli B, Poggioli G (2016) Treatment of minor dehiscence after endorectal advancement flap in perianal Crohn's fistulas with ozonized oil Novox®. *Tech Coloproctol* 20(2): 139–40
- Lee RC (1997) Injury by electrical forces: pathophysiology, manifestations, and therapy. *Curr Probl Surg* 34, 677–764
- Lund CC, Browder NC (1944) The estimation of areas of burns. *Surg Gynecol Obstetr* 79: 352–8
- Mamounas EP, Fisher B (2001) Preoperative (neoadjuvant) chemotherapy in patients with breast cancer. *Semin Oncol* 28(4): 389–99
- Markiewicz-Gospodarek A, Koziol M, Tobiasz M et al (2022) Burn wound healing: clinical complications, medical care, treatment, and dressing types: the current state of knowledge for clinical practice. *Int J Environ Res Public Health* 19(3): 1338
- Santorelli A, Bernini M, Orzalesi L et al (2021) Treatment with oxygen-enriched olive oil improves healing parameters following augmentation-mastopexy. *Aesthet Surg J Open Forum* 3(3): ojab016
- Schneider JC, Harris NL, El Shami A et al (2006) A descriptive review of neuropathic-like pain after burn injury. *J Burn Care Res* 27(4): 524–8
- Sies H (2020) Oxidative stress: concept and some practical aspects. *Antioxidants (Basel)* 9(9): 852
- Smolle C, Cambiaso-Daniel J, Forbes AA et al (2017) Recent trends in burn epidemiology worldwide: a systematic review. *Burns* 43(2): 249–57
- Sri R (2022) *La Malattia da Ustione. Una patologia rara e cronica non riconosciuta nei LEA*. Osservatorio malattie rare RareLab. Available from: www.osservatoriomalattierare.it/progetti/le-nostre-pubblicazioni/18619-la-malattia-da-ustione-patologia-rara-orfana-dei-lea (accessed 13.05.2022)
- Um JY, Kim HB, Kim JC et al (2022) TRPV3 and itch: the role of TRPV3 in chronic pruritus according to clinical and experimental evidence. *Int J Mol Sci* 23(23): 14962
- Van Loey NE, Bremer M, Faber AW et al (2008) Itching following burns: epidemiology and predictors. *Br J Dermatol* 158(1): 95–100
- Vitale M, Fields-Blache C, Luterman A (1991) Severe itching in the patient with burns. *J Burn Care Rehabil* 12(4): 330–3
- Willebrand M, Low A, Dyster-Aas J et al (2004) Pruritus, personality traits and coping in long-term follow-up of burn-injured patients. *Acta Derm Venereol* 84(5): 375–80
- Zachariah JR, Rao AL, Prabha R et al (2012) Post burn pruritus: a review of current treatment options. *Burns* 38(5): 621–9